



# Microfracture augmented with allograft cartilage and autologous platelet-rich plasma improves function after hip arthroscopy: A short-term analysis

I. AL'KHAFAJI<sup>1</sup>, T. LUO<sup>2</sup>, A. TRAMMELL<sup>2</sup>, T. VANHORN<sup>2</sup>, M. KOULOPOULOS<sup>2</sup>, A. MARQUEZ-LARA<sup>2</sup>, M. SCHALLMO<sup>2</sup>, S. ROSAS<sup>2</sup>, and A. STUBBS<sup>2</sup>1

1. Kerlan-Jobe Institute, Santa Monica, CA, USA

2. Wake Forest Baptist Medical Center, Winston-Salem, NC, USA

## INTRODUCTION

Articular cartilage injuries of the hip are challenging to treat. Due to the limited healing capacity of cartilage, these lesions can progress to arthritic joint changes and are often diagnosed during hip arthroscopy as they are associated with labral tears and femoroacetabular impingement. These defects occur most frequently in the anterosuperior aspect of the acetabulum.

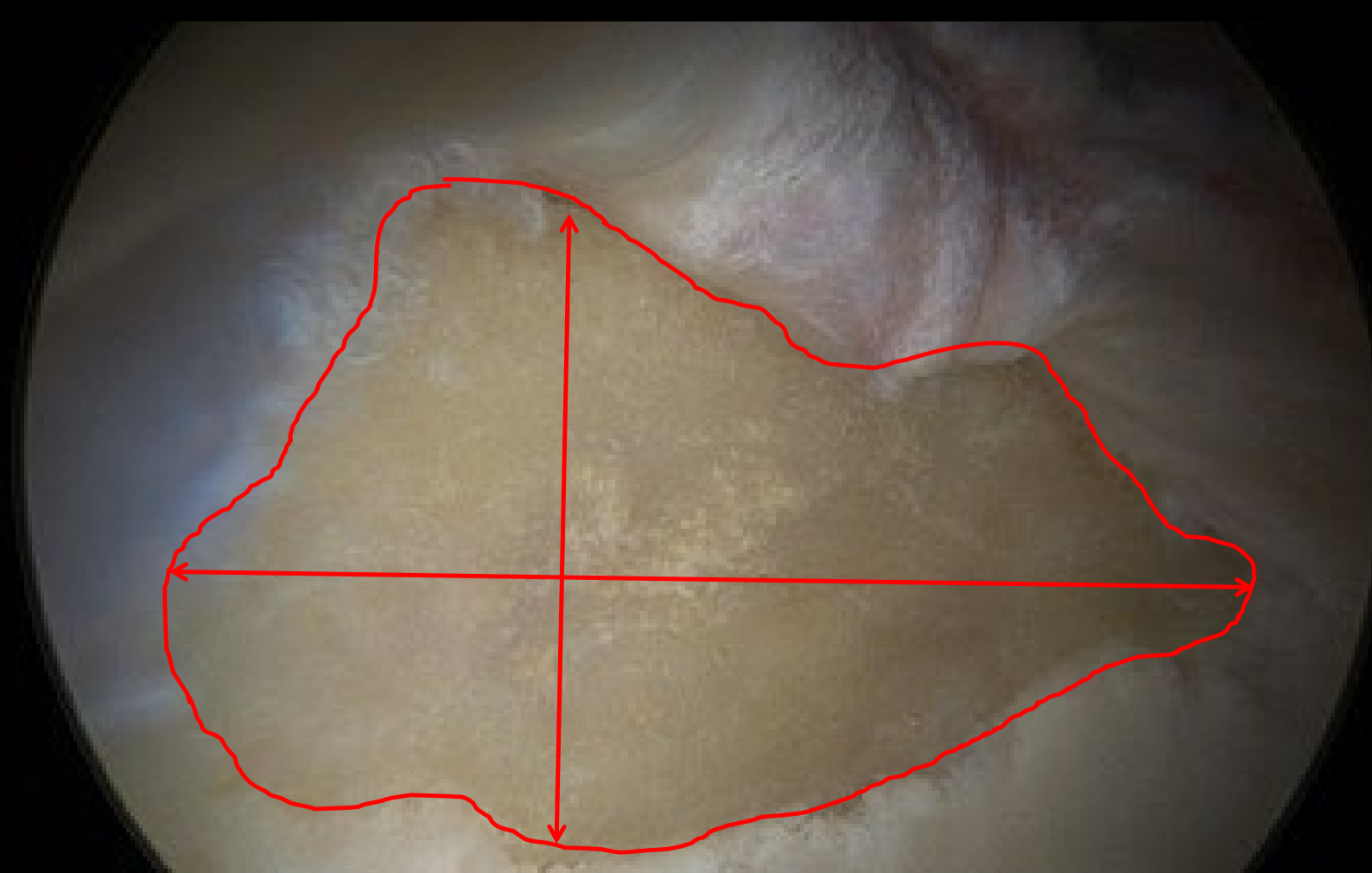
A novel technique using biologic scaffolds combining minced allograft cartilage and autologous platelet-rich plasma (BioCartilage®, Arthrex, Naples, FL) has been introduced to augment microfracture treatment of symptomatic chondral defects.

## AIM

The purpose of this study was to evaluate short-term outcomes in a series of patients who underwent hip arthroscopy with biologically augmented microfracture procedures. We hypothesized that patients who undergo this procedure would demonstrate significant improvements in clinical outcome scores at one year postoperatively.

## METHOD

- Prospective case series of adult patients (age ≥ 18) with symptomatic hip pain and high-grade chondromalacia (Outerbridge IV)
- Previously failed conservative management
- Cartilage degeneration quantified using a previously reported chondromalacia severity index (CMI): product of Outerbridge grade and estimated affected surface area (mm<sup>2</sup>) for each chondral lesion



- Patient-reported outcomes were collected preoperatively and at minimum one-year postoperatively.

## RESULTS

N=13 (7 females, 6 males)

Mean age 32.5 ± 8.7 years

Mean BMI of 29.4 ± 5.3 kg/m<sup>2</sup>

All patients demonstrated severe acetabular chondromalacia with mean CMI of 641.2 grade x mm<sup>2</sup>

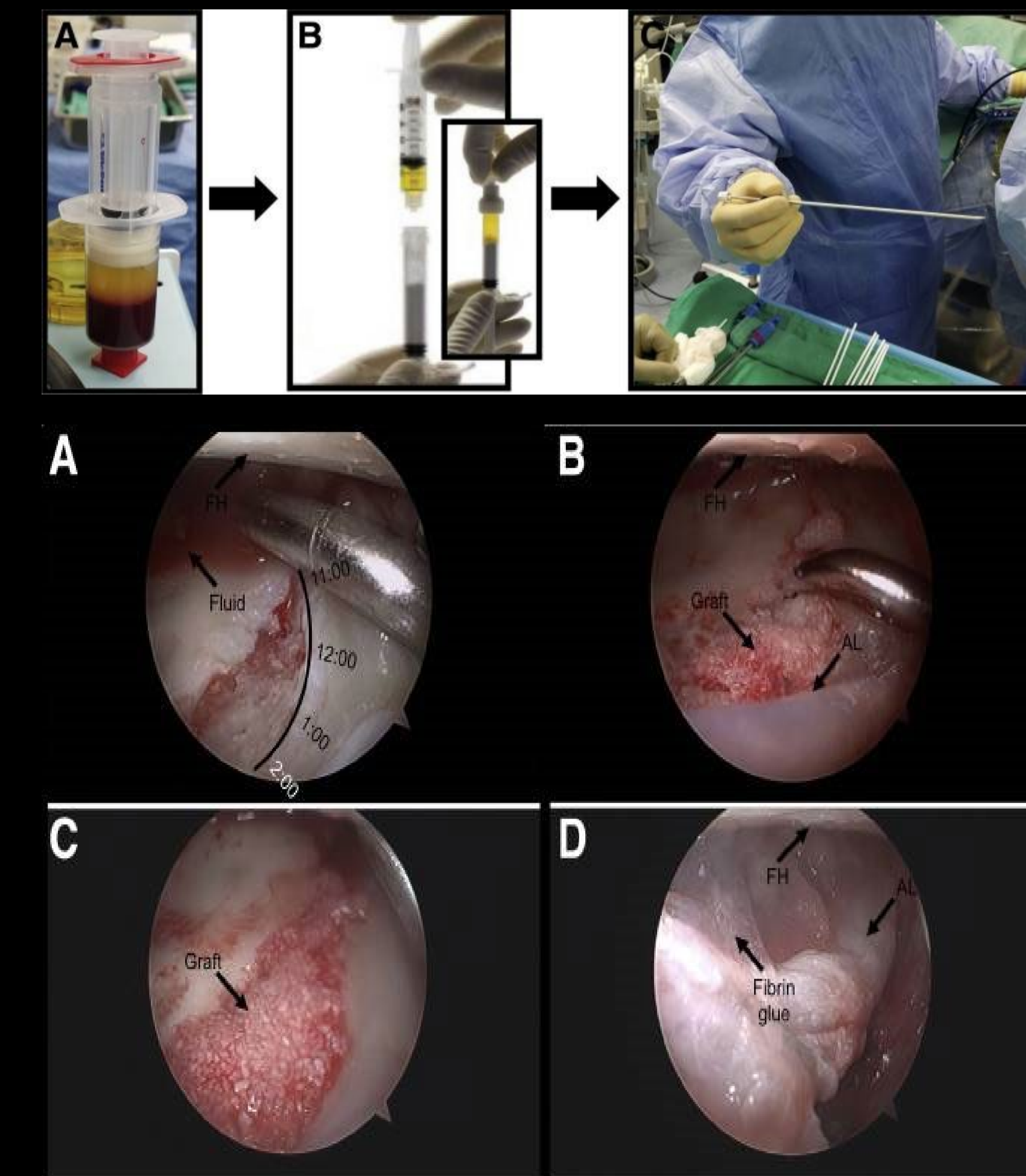
9/13 patients demonstrated femoral head chondromalacia with mean CMI of 394.2 grade x mm<sup>2</sup>

1 patient underwent THA 12 months after hip arthroscopy [history of previous femoral osteotomies and screw fixation for treatment of slipped capital femoral epiphysis (SCFE)]

9/12 patients (75%) who did not have prior hip surgical intervention were available for followup at mean of 15.4 months (minimum 12.2 months)

Significant improvements in patient-reported outcomes (PROs) were seen at 1 year (Table 1)

PRO	Preoperative score	Postoperative score	p-value
Modified Harris Hip Score	59.3 ± 12.8	89.8 ± 16.6	0.002
Hip Outcome Score-ADL	64.0 ± 16.7	95.3 ± 9.2	0.003
Hip Outcome Score-SSS	42.6 ± 26.1	90.9 ± 16.0	0.002
Nonarthritic Hip Score	62.2 ± 14.3	90.1 ± 16.3	0.005
Tegner Score	4.3 ± 3.5	5.6 ± 2.7	0.104



- A. Preoperative peripheral blood draw to prepare platelet-rich plasma (PRP).
- B. Dehydrated scaffold (bottom) mixed with PRP in mixing syringe.
- C. Arthroscopic delivery needle is loaded with prepared graft from mixing needle.

- A. Superior acetabular chondral lesion after microfracture.
- B. Introduction of graft via delivery needle.
- C. Arthroscopic elevator used to smooth the graft and create slight recess within the lesion.
- D. Repaired chondral lesion after fibrin glue application and traction is slowly released.

## CONCLUSIONS

Early experience with this technique supports the concept that biological augmentation of microfracture with has similar indications, is equally safe, is simple to perform, and may lead to better overall restoration of the articular surface compared with microfracture alone.

Patients without prior hip procedures demonstrated significant functional improvements with microfracture with biologic augmentation at one-year. The patient who failed microfracture treatment had multiple prior hip procedures for SCFE, including previous femoral osteotomy, and exhibited substantial bipolar hip pathology, highlighting the need for further research to optimize patient selection for this novel technique.

## REFERENCES

1. Buckwalter JA. Articular cartilage: injuries and potential for healing. J Orthop Sports Phys Ther. 1998;28(4):192-202.
2. Bedi A, Feeley BT, Williams RJ, 3rd. Management of articular cartilage defects of the knee. J Bone Joint Surg Am. 2010;92(4):994-1009.
3. Marquez-Lara A, Mannava S, Howse EA, Stone AV, Stubbs AJ. Arthroscopic Management of Hip Chondral Defects: A Systematic Review of the Literature. Arthroscopy. 2016;32(7):1435-43.
4. McCarthy JC, Lee JA. Arthroscopic intervention in early hip disease. Clin Orthop Relat Res. 2004(429):157-62.
5. Yen YM, Kocher MS. Chondral lesions of the hip: microfracture and chondroplasty. Sports Med Arthrosc Rev. 2010;18(2):83-9.
6. Bae DK, Yoon KH, Song SJ. Cartilage healing after microfracture in osteoarthritic knees. Arthroscopy. 2006;22(4):367-74.
7. Domb BG, Rybalko D, Mu B, Litrenta J, Chen AW, Perets I. Acetabular microfracture in hip arthroscopy: clinical outcomes with minimum 5-year follow-up. Hip Int. 2018;1120700018760263.
8. Trask DJ, Keene JS. Analysis of the Current Indications for Microfracture of Chondral Lesions in the Hip Joint. Am J Sports Med. 2016;44(12):3070-6.
9. Schallmo MS, Marquez-Lara A, Luo TD, Rosas S, Stubbs AJ. Arthroscopic Treatment of Hip Chondral Defect With Microfracture and Platelet-Rich Plasma-Infused Micronized Cartilage Allograft Augmentation. Arthrosc Tech. 2018;7(4):e361-e5.
10. Fortier LA, Chapman HS, Pownder SL, Roller BL, Cross JA, Cook JL, et al. BioCartilage Improves Cartilage Repair Compared With Microfracture Alone in an Equine Model of Full-Thickness Cartilage Loss. Am J Sports Med. 2016;44(9):2366-74.

## CONTACT INFORMATION

Ian Al'Khafaji, M.D. (ialkhafa@gmail.com)  
Kerlan-Jobe Institute  
Cedar-Saini Medical Center  
2020 Santa Monica Blvd  
Santa Monica, CA 90404, USA

