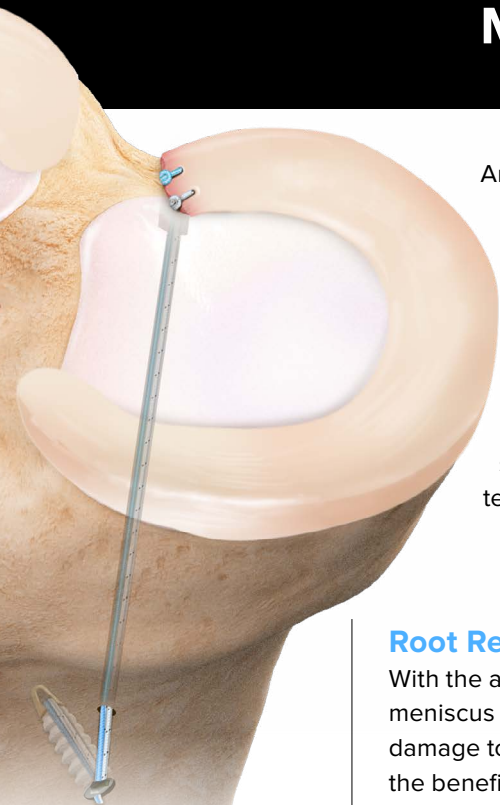


Meniscus Root Repair Scientific Update



Zheng T,
Song G,
Li Y,
et al

Chang PS,
Radtke L,
Ward P,
Brophy RH

An increase in published orthopedic literature regarding meniscus function, pathology, and repair is leading to increased understanding of the importance of meniscal preservation. The meniscus is a fibrocartilaginous structure in each compartment of the knee that aids with dispersing compressive forces. Multiple pathologies, such as direct trauma, overuse, previous injury, and increased age, can lead to meniscus damage.

Advancements in technology and innovation have produced better techniques and instrumentation for meniscus repair. This document summarizes published studies that describe the meniscus anatomy, biomechanical data, surgical techniques, and clinical data.

Root Repair

With the advancements in arthroscopic techniques, tears in the posterior root of the meniscus are more frequently recognized. If not repaired, root tears can cause further damage to the joint and increase the rate of arthritis. Below are recent studies determining the benefits of and biomechanical effects from repairing the meniscal root.

[Clinical, radiographic, and arthroscopic outcomes of surgical repair for radial and avulsed lesions on the lateral meniscus posterior root during ACL reconstruction: a systematic review.](#) *Orthop J Sports Med.* 2021;9(3):2325967121989678. doi:10.1177/2325967121989678

- Patients with tears of the lateral meniscus posterior root (LMPR) associated with anterior cruciate ligament (ACL) injuries obtained favorable functional scores after simultaneous anterior cruciate ligament reconstruction (ACLR) and LMPR repairs.
- >90% of side-to-side radial tear repairs showed complete or partial healing upon second-look arthroscopy.
- Radiographical outcomes at 33.9 months postop showed no significant progression of joint space narrowing or chondral lesions of the lateral meniscus.

Takeaway

The most important finding was that complete or partial healing was found in 93.6% of the second-look arthroscopies after side-to-side repairs for radial tears of the posterior root.

[Midterm outcomes of posterior medial meniscus root tear repair: a systematic review.](#) *Am J Sports Med.* 2021;363546521998297. doi:10.1177/0363546521998297

- A systemic analysis of 28 studies demonstrated improved clinical outcomes (Lysholm, IKDC, Hospital for Special Surgery, and Tegner scores) associated with posterior medial meniscus root tear (PMMRT) repair.
- Some of the studies included in the systemic review revealed that PMMRT repair was shown to slow the progression of osteoarthritis but does not prevent it at midterm follow-up.

Takeaway

The most important finding of this study was that repairs of posterior medial meniscus root tears provide a functional benefit with consistent improvement in clinical outcome scores.

Bernard CD,
Kennedy NI,
Tagliero AJ,
et al

[Medial meniscus posterior root tear treatment: a matched cohort comparison of nonoperative management, partial meniscectomy, and repair.](#) *Am J Sports Med.* 2020;48(1):128-132. doi:10.1177/0363546519888212

- Medial meniscus posterior horn root tears consist of 10% to 21% of all meniscal tears.
- Meniscus root repair leads to less arthritis progression and subsequent knee arthroplasty compared with nonoperative management and partial meniscectomy.
- Meniscectomy for root tear leads to an increase need for knee arthroplasty.

Takeaway

The most important finding of this study is that meniscus root repair leads to significantly less arthritis progression and subsequent knee arthroplasty compared with nonoperative management and partial meniscectomy.

Kennedy MI,
Strauss M,
LaPrade RF

[Injury of the meniscus root.](#) *Clin Sports Med.* 2020;39(1):57-68. doi:10.1016/j.csm.2019.08.009

- This study found medial posterior root tears are more common (52%) than lateral posterior root tears (41%).
- Disruption of root tears often lead to meniscus extrusion and failure of load distribution.
- Increased contact pressure and stresses are incurred with posterior root disruption.
- The absence of a lateral posterior meniscus attachment results in greater strain placed on ACL and increased anterior tibial translation and internal rotation.
- Medial posterior meniscus horn detachment increases medial compartment contact pressures and alters load distribution.
- Proper anatomic root repairs restore knee stability and joint loading.
- Patients with no to mild osteoarthritis (OA) have significantly improved outcomes following posterior root repair and stall the progression of OA.

Takeaway

This article is a great introduction to the importance of root repair.

Krych AJ,
Bernard CD,
Kennedy NI,
et al

[Medial versus lateral meniscus root tears: is there a difference in injury presentation, treatment decisions, and surgical repair outcomes?](#) *Arthroscopy.* 2020;36(4):1135-1141. doi:10.1016/j.arthro.2019.11.098

- The purpose of this journal article is to use demographic characteristics, radiographic findings, treatment decisions, clinical outcomes, and risk factors to compare medial and lateral meniscus root tears.
- A retrospective review was performed to identify patients with symptomatic, medial, or lateral meniscus posterior root tears with a minimum 2-year follow-up.
- Of the 141 root tears that were identified, 109 were medial meniscus root tears and 30 were lateral meniscus root tears.

Takeaway

The authors concluded that when compared to MMRTs, LMRTs occur in younger male patients with lower body mass index, less cartilage degeneration, less extrusion on MRI, and commonly with a ligament injury. The authors also concluded that LMRTs may have better results after repair, suggesting that differences in injury and patient characteristics may contribute to differences in these outcomes.



Faucett SC,
Geisler BP,
Chahla J,
et al

[Meniscus root repair vs meniscectomy or nonoperative management to prevent knee osteoarthritis after medial meniscus root tears: clinical and economic effectiveness.](#) *Am J Sports Med.* 2019;47(3):762-769. doi:10.1177/0363546518755754

- Patients who were treated with a meniscectomy or nonoperative treatment for a medial meniscus root tear showed 99.3% and 95.1% rates of osteoarthritis respectively over a 10-year period.
- 53% of patients who received a medial meniscus root repair showed a progression of osteoarthritis over 10 years.
- During the same 10-year period, only 33.5% of patients who received a medial meniscus root repair went on to knee arthroplasty compared to 51.5% and 45.5% of patients who received a meniscectomy or nonoperative treatment, respectively.

Takeaway

Medial meniscus root repairs lead to less osteoarthritis compared to total meniscectomy and nonsurgical treatment.

Forkel P,
von Deimling C,
Lacheta L,
et al

[Repair of the lateral posterior meniscal root improves stability in an ACL-deficient knee.](#) *Knee Surg Sports Traumatol Arthrosc.* 2018;26(8):2302-2309. doi:10.1007/s00167-018-4949-8

- This human cadaveric study of eight knees looks at 5 different scenarios: intact, ACL cut, ACL cut and lateral meniscus posterior root tear, ACL cut and lateral meniscus posterior root tear and transection of meniscal femoral ligament, and ACL cut with lateral meniscus posterior root tear.
- Lateral meniscus posterior root tear increased internal tibial instability compared to an ACL-insufficient knee.
- Lateral meniscus posterior root repair significantly decreases internal tibial rotation in an ACL-deficient knee.

Takeaway

Repairing a lateral posterior meniscus root tear along with ACL reconstruction can improve rotational stability.

Krych AJ,
Reardon PJ,
Johnson NR,
et al

[Non-operative management of medial meniscus posterior horn root tears is associated with worsening arthritis and poor clinical outcome at 5-year follow-up.](#) *Knee Surg Sports Traumatol Arthrosc.* 2017;25(2):383-389. doi:10.1007/s00167-016-4359-8

- Nonoperative treatment of medial meniscus posterior horn root tears is associated with progression of arthritis and a relatively high rate of arthroplasty at 5-year follow-up.
- Nonoperative treatment resulted in 31% of patients progressing to knee arthroplasty within 30 months of the initial diagnosis.
- Overall, 87% of patients failed nonoperative treatment.

Takeaway

Nonoperative treatment of medial meniscus posterior horn root tears is associated with poor clinical outcome, worsening arthritis, and a relatively high rate of arthroplasty at 5-year follow-up.



LaPrade RF,
LaPrade CM,
Ellman MB,
Turnbull TL,
Cerinara AJ,
Wijdicks CA

[Cyclic displacement after meniscal root repair fixation: a human biomechanical evaluation.](#)

AM J Sports Med. 2015;43(4):892-898. doi:10.1177/0363546514562554

- This cadaveric study compares 4 different suture configurations for meniscal root repair.
- The authors evaluated root repairs using a two-simple suture (TSS) technique, a modified Mason-Allen (MMA) suture technique, a single double-locking loop (S-DLL) technique, and a double double-locking loop (D-DLL) technique.
- Following 1000 cycles of each specimen, displacement was measured and revealed that the TSS technique displaced the least, followed by the MMA, D-DLL and S-DLL techniques.

Takeaway

The authors conclude that the TSS fixation is sufficient at resisting displacement and demonstrates ultimate failure loads above currently accepted thresholds.

LaPrade CM,
Foad A,
Smith SD,
et al

[Biomechanical consequences of a nonanatomic posterior medial meniscal root repair.](#) *Am J Sports Med.* 2015;43(4):912-920. doi:10.1177/0363546514566191

Am J Sports Med. 2015;43(4):912-920. doi:10.1177/0363546514566191

- Nonanatomical posterior medial root repair did not restore contact area of mean contact pressures to that of the intact knee or when compared to an anatomical repair.
- Anatomic repair of the posterior medial meniscus horn decreased contact area by only 17% compared to a 44% decrease of contact area when nonanatomically repaired.
- Contact pressures of a nonanatomically repaired posterior medial root repair increased by 67% compared with an intact posterior medial meniscus root.

Takeaway

Anatomic placement of the root is crucial for healing. Nonanatomic repair did not restore the contact area or mean contact pressures to that of the intact knee or anatomic repair.

Chung KS,
Ha JK,
Yeom CH,
et al

[Comparison of clinical and radiologic results between partial meniscectomy and refixation of medial meniscus posterior root tears: a minimum 5-year follow-up.](#) *Arthroscopy.*

2015;31(10):1941-1950. doi:10.1016/j.arthro.2015.03.035

- In this study, 57 patients were followed for a minimum of 5 years following partial meniscectomy and medial meniscus posterior horn repair.
- Clinical assessments included Lysholm scores and IKDC scores.
- Radiological assessments were evaluated using Kellgren-Lawrence (K-L) grading and joint space evaluation.
- Repair group had significantly better clinical results when compared to meniscectomy group and showed less K-L grade progression and less joint narrowing.
- Of meniscectomized knees, 3% received a total knee arthroplasty within 5 years while none of the repair group received a total knee arthroplasty.

Takeaway

Refixation of the meniscus root was more effective than partial meniscectomy and slowed the progression of arthritic changes.



Padalecki JR,
Jansson KS,
Smith SD,
et al

[Biomechanical consequences of a complete radial tear adjacent to the medial meniscus posterior root attachment site: in situ pull-out repair restores derangement of joint mechanics.](#) *Am J Sports Med.* 2014;42(3):699-707. doi:10.1177/0363546513499314

- Radial tears near the posterior root of the medial meniscus can compromise circumferential integrity, can result in extrusion, and are challenging to treat surgically.
- Repair of these radial tears with an in situ pull-out technique restores the loading profiles of the medial compartment.

Takeaway

Reanchoring the posterior horn in patients with complete radial tears would have a favorable biomechanical effect.

Moon HK,
Koh YG,
Kim YC,
Park YS,
Jo SB,
Kwon SK

[Prognostic factors of arthroscopic pull-out repair for a posterior root tear of the medial meniscus.](#) *Am J Sports Med.* 2012;40(5):1138-1143. doi:10.1177/0363546511435622

- Second-look arthroscopy of ten patients following medial meniscal root tear repair showed complete healing of all ten menisci without additional chondral lesions.
- Medial meniscal root tear repair alone failed to prevent the progression of meniscus extrusion.
- Patients with $>5^\circ$ of varus alignment experienced better medial meniscus root repair outcomes when combined with a correctional osteotomy.

Takeaway

All clinical outcome measures significantly improved after a medial meniscus root repair, and the technique provided patients with a clinical benefit.

Lee JH,
Lim YJ,
Kim KB,
Kim KH,
Song JH

[Arthroscopic pullout suture repair of posterior root tear of the medial meniscus: radiographic and clinical results with 2-year follow-up.](#) *Arthroscopy.* 2009;25(9):951-958. doi:10.1016/j.arthro.2009.03.018

- Twenty-six patients received arthroscopic posterior medial root repair using a transtibial technique and a minimum of two-year follow-up of clinical and radiographic evaluation along with ten second-look arthroscopies.
- Upon second-look arthroscopies of ten randomly selected patients, it was determined that all menisci had healed completely, and no additional chondral lesions were noted.
- Hospital for Special Surgery clinical scores improved from 61.1 preoperatively to 93.8 at final follow-up. Lysholm knee scores were 93.1 at final follow-up from 57 preoperatively.

Takeaway

The authors concluded that arthroscopic transtibial repair technique of patients that are symptomatic is an effective treatment of posterior medial meniscus root tears.



[Biomechanical consequences of a tear of the posterior root of the medial meniscus. surgical technique. J Bone Joint Surg Am. 2009;91\(2\):257-270. doi:10.2106/JBJS.I.00500](#)

- This was a human cadaveric study at the University of Pittsburgh comparing an intact medial meniscus, a posterior root tear of the medial meniscus, a transtibially repaired posterior root tear, and total meniscectomy.
- An axial load of 1000 N was applied to the specimen and contact pressures measured at knee flexion angles of 0°, 30°, 60° and 90°.
- Contact pressures increased 25% in the specimen with a medial meniscus posterior root tear.
- The transtibially repair group demonstrated restored normal peak contact pressures and restored joint biomechanics.
- Peak contact pressures in the lateral compartment along with increases in external rotation and lateral tibial translation were observed with medial root disruption.
- Contact pressures, external rotation, and lateral translation all returned to normal levels following posterior horn medial meniscus repair.

Takeaway

This study demonstrates that posterior root tears cause significant changes in contact pressure and knee joint kinematics. Root repair was successful in restoring joint biomechanics to within normal conditions.